

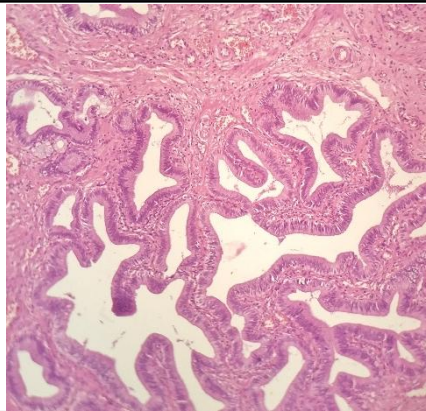
<b>Patient Name</b>	ROMI JAN 8497	<b>Client Name</b>	Patients Care Clinical	<b>Specimen Received</b>	12/04/2019
<b>Age/Sex</b>	20 YRS/F		Laboratory, Jammu & Kashmir	<b>Specimen Type</b>	Tissue
<b>Patient ID</b>	011904120143	<b>Client Code</b>		<b>Collection Date</b>	12/04/2019
<b>Specimen ID</b>	MOLQ/B-636/19	<b>Ref. Doctor</b>		<b>Report Date</b>	15/04/2019

## SURGICAL PATHOLOGY REPORT

### Gall bladder

#### DIAGNOSIS

**CHOLECYSTITIS**



#### **SPECIMEN**

Gall bladder

#### **GROSS**

Received 6.2x2.8cm long gall bladder already cut open without stones.

#### **Microscopy**

1. Section examined shows ulcerative mucosa and Rokitansky-Aschoff sinus (irregularly shaped tubular structures lined by cuboidal lining epithelium with round to oval nucleus) with fibro collagenous tissue and inflammatory cells (lymphocytes).

**Note :** All biopsy specimen will be stored for 15 (fifteen) days, block and slides for 5 (five) years only from the time of receipt at the laboratory. No request, for any of the above, will be entertained after the due date.

#### **Reference**

- i) Rosai and Ackerman's Surgical Pathology.
- ii) Modern Surgical Pathology.

**Gulshan Yadav, MD  
Consultant Pathologist**