

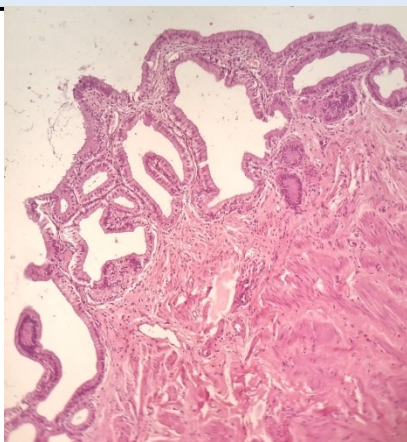
<b>Patient Name</b>	Mrs. ASHA	<b>Client</b>	Civil Hospital-P	<b>Specimen Received</b>	10/04/2019
<b>Age/Sex</b>	30 YRS/F			<b>Specimen Type</b>	Tissue
<b>Patient ID</b>	011904100288			<b>Collection Date</b>	10/04/2019
<b>Specimen ID</b>	MOLQ/B-630/19			<b>Report Date</b>	12/04/2019

## SURGICAL PATHOLOGY REPORT

### Gall bladder

#### DIAGNOSIS

**CHOLECYSTITIS WITH CHOLELITHIASIS**



#### SPECIMEN

Gall bladder

#### GROSS

Received 5x2.6cm long gall bladder already cut open with stones.

#### Microscopy

- Section examined shows ulcerative mucosa and Rokitansky-Aschoff sinuses (irregularly shaped tubular structures lined by cuboidal lining epithelium with round to oval nucleus) with fibrocollagenous tissue and inflammatory cells (lymphocytes).

**Note :** All biopsy specimen will be stored for 15 (fifteen) days, block and slides for 5 (five) years only from the time of receipt at the laboratory. No request, for any of the above, will be entertained after the due date.

#### Reference

- Rosai and Ackerman's Surgical Pathology.
- Modern Surgical Pathology.

**Gulshan Yadav, MD**  
Consultant Pathologist