

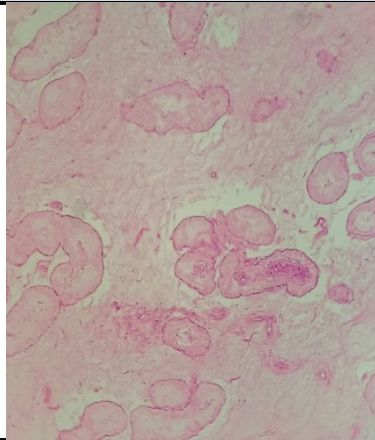
| | | | | | |
|---------------------|----------------------|--------------------|-----------------------------|--------------------------|------------|
| Patient Name | Mr. HAMID ULLAH 8382 | Client Name | Patients Care Clinical | Specimen Received | 06/04/2019 |
| Age/Sex | 55 YRS/M | | Laboratory, Jammu & Kashmir | Specimen Type | Tissue |
| Patient ID | 011904050434 | Client Code | | Collection Date | 06/04/2019 |
| Specimen ID | MOLQ/B-607/19 | | | Report Date | 13/04/2019 |

SURGICAL PATHOLOGY REPORT

Testes

DIAGNOSIS

Atrophic testes



SPECIMEN

Testes

GROSS

Received 5x2.6cm testes with epididymis .

Microscopy

1. Section examined shows seminiferous tubules with occasional mature spermatogenic cells with thick basement membrane.
2. Epididymis shows mature supporting cells surrounding fibrocollagenous tissue and epididymis unremarkable.
3. Surrounding tissue unremarkable.

Note : All biopsy specimen will be stored for 15 (fifteen)days, block and slides for 5(five) years only from the time of receipt at the laboratory. No request ,for any of the above ,will be entertained after the due date.

Reference

- i) Rosai and Ackerman's Surgical Pathology.
- ii) Modern Surgical Pathology.

Gulshan Yadav, MD
Consultant Pathologist