

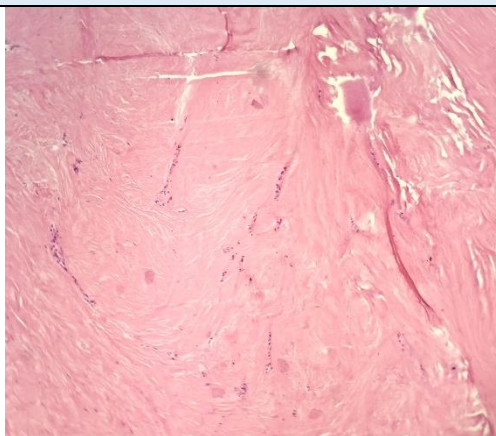
| | | | | | |
|---------------------|-----------------------------|--------------------|--------------|--------------------------|------------|
| Patient Name | Ms. MADHU BALA SINGH | Client Name | K R Hospital | Specimen Received | 03/04/2019 |
| Age/Sex | 45 YRS/F | | Delhi | Specimen Type | Tissue |
| Patient ID | 011904030220 | Client Code | MolQ1376P | Collection Date | 03/04/2019 |
| Specimen ID | MOLQ/B-584/19 | | | Report Date | 13/04/2019 |

SURGICAL PATHOLOGY REPORT

Chronic non-healing ulcer of calcareum.

DIAGNOSIS

HYPERKERATOSIS WITH GRANULATION TISSUE



SPECIMEN

Chronic non-healing ulcer of calcareum. .

GROSS

Received multiple greyish white tissue piece.

Microscopy

1. Section examined shows hyperkeratosis with squamous lining epithelium with granulation tissue, few calcified areas also seen.

Note : All biopsy specimen will be stored for 15 (fifteen) days, block and slides for 5 (five) years only from the time of receipt at the laboratory. No request, for any of the above, will be entertained after the due date.

Reference

- i) Rosai and Ackerman's Surgical Pathology.
- ii) Modern Surgical Pathology.

A handwritten signature in black ink, appearing to read 'Gulshan', written over a light blue rectangular background.

**Gulshan Yadav, MD
Consultant Pathologist**