

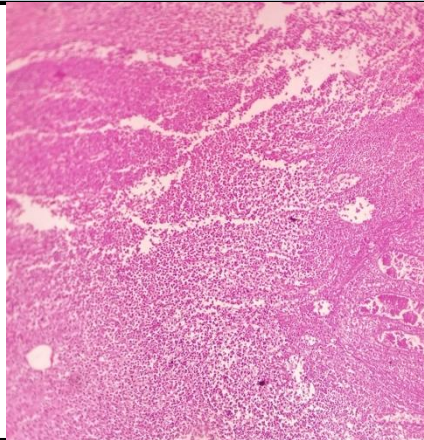
Patient Name	HARISH	Client Name	Civil Hospital-P	Specimen Received	09/04/2019
Age/Sex	27 YRS/M	Client Code		Specimen Type	Tissue
Patient ID	011904090407			Collection Date	09/04/2019
Specimen ID	MOLQ/B-623/19			Report Date	11/04/2019

SURGICAL PATHOLOGY REPORT

Appendix

DIAGNOSIS

ACUTE APPENDICITIS



SPECIMEN

Appendix

GROSS

Received autolyzed 7x1.2cm long appendix Cut section shows fecolith and blood clot .

Microscopy

- Section examined shows lymphoid follicles with ulcerative mucosa. Deeper tissue shows inflammatory cells (polymorphs, lymphocytes and few histiocytes).

Note : All biopsy specimen will be stored for 15 (fifteen)days, block and slides for 5(five) years only from the time of receipt at the laboratory. No request ,for any of the above ,will be entertained after the due date.

Reference

- Rosai and Ackerman's Surgical Pathology.
- Modern Surgical Pathology.

Gulshan Yadav, MD
Consultant Pathologist