

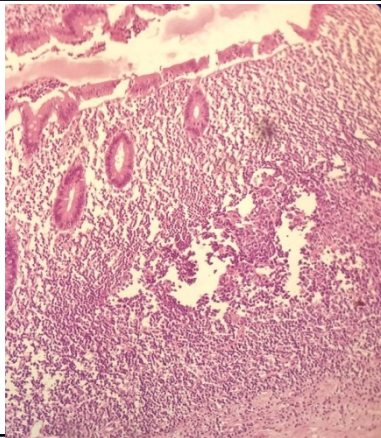
Patient Name	Mrs. BEENA	Client Name	Path Star Diagnostic	Specimen Received	08/04/2019
Age/Sex	33 YRS/F	Client Code		Specimen Type	Tissue
Patient ID	011904080137			Collection Date	08/04/2019
Specimen ID	MOLQ/B-621/19			Report Date	11/04/2019

SURGICAL PATHOLOGY REPORT

Appendix

DIAGNOSIS

ACUTE APPENDICITIS



SPECIMEN

Appendix

GROSS

Received 6.1cm long appendix with mesoappendix cut section shows fecolith.

Microscopy

- Section examined shows lymphoid follicles with ulcerative mucosa. Deeper tissue shows inflammatory cells (polymorphs, lymphocytes and few histiocytes).

Note : All biopsy specimen will be stored for 15 (fifteen) days, block and slides for 5 (five) years only from the time of receipt at the laboratory. No request, for any of the above, will be entertained after the due date.

Reference

- Rosai and Ackerman's Surgical Pathology.
- Modern Surgical Pathology.

Gulshan Yadav, MD
Consultant Pathologist