

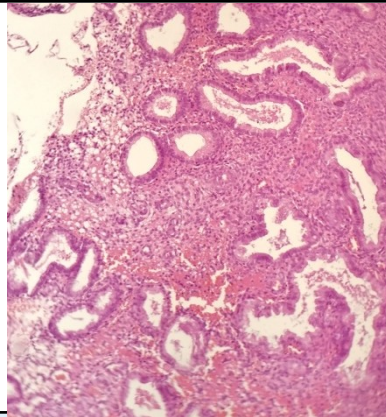
Patient Name	Mrs. RENU	Client Name	Path Star Diagnostic	Specimen Received	08/04/2019
Age/Sex	39 Years/Female	Client Code	MOLQ1098CM	Specimen Type	Tissue
Patient ID	011904080133	Ref. Doctor		Collection Date	08/04/2019
Specimen ID	MOLQ/B-616/19			Report Date	10/04/2019

SURGICAL PATHOLOGY REPORT

Endometrium

DIAGNOSIS

Disordered proliferative phase.



SPECIMEN

Endometrium

GROSS

Received multiple greyish white tissue piece.

Microscopy

1. Section examined shows small and tortuous endometrial glands, columnar lining squamous metaplasia.

Stroma shows mononuclear inflammatory cells and lumen show vacuolization.

Note : All biopsy specimen will be stored for 15 (fifteen) days, block and slides for 5 (five) years only from the time of receipt at the laboratory. No request, for any of the above, will be entertained after the due date.

Reference

- i) Rosai and Ackerman's Surgical Pathology.
- ii) Modern Surgical Pathology.

Gulshan Yadav, MD
Consultant Pathologist