

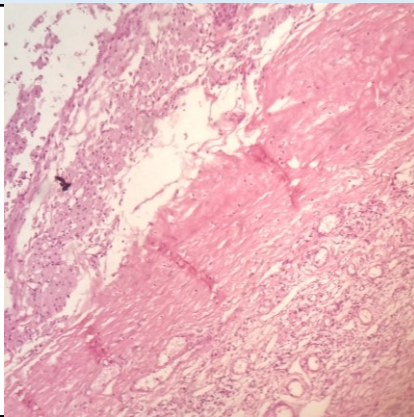
|                     |                            |                    |                             |                          |            |
|---------------------|----------------------------|--------------------|-----------------------------|--------------------------|------------|
| <b>Patient Name</b> | <b>Ms. NIGHAT WO AABID</b> | <b>Client Name</b> | Patients Care Clinical      | <b>Specimen Received</b> | 06/04/2019 |
| <b>Age/Sex</b>      | 32 Years/Female            |                    | Laboratory, Jammu & Kashmir | <b>Specimen Type</b>     | Tissue     |
| <b>Patient ID</b>   | 011904050411               | <b>Client Code</b> | MolQ1839P                   | <b>Collection Date</b>   | 06/04/2019 |
| <b>Specimen ID</b>  | MOLQ/B-609/19              | <b>Ref. Doctor</b> |                             | <b>Report Date</b>       | 10/04/2019 |

## SURGICAL PATHOLOGY REPORT

### Left ovarian cyst

#### DIAGNOSIS

**DERMOID CYST**



#### SPECIMEN

Left ovarian cyst

#### GROSS

Received 8x4cm cystic tissue piece with hair and necrosis.

#### Microscopy

- Section examined shows lining epithelium with round to oval nucleus, fibrocollagenous tissue, adipose cells, blood vessels, and sebaceous glands. No granuloma and no malignant cells seen.

**Note :** All biopsy specimen will be stored for 15 (fifteen)days, block and slides for 5(five) years only from the time of receipt at the laboratory. No request ,for any of the above ,will be entertained after the due date.

#### Reference

- Rosai and Ackerman's Surgical Pathology.
- Modern Surgical Pathology.

**Gulshan Yadav, MD**  
Consultant Pathologist