

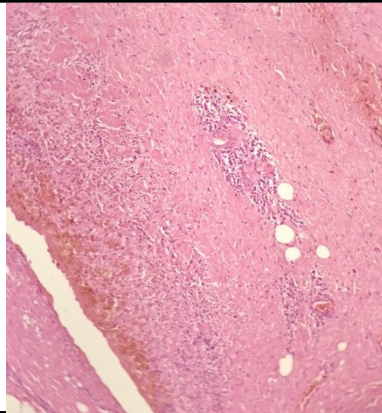
| | | | | | |
|---------------------|-----------------|--------------------|---------------------|--------------------------|------------|
| Patient Name | Mrs. REENA | Client Name | Arban Hospital, Nuh | Specimen Received | 08/04/2019 |
| Age/Sex | 38 Years/Female | Client Code | MolQ1684P | Specimen Type | Tissue |
| Patient ID | 011904050350 | Ref. Doctor | | Collection Date | 08/04/2019 |
| Specimen ID | MOLQ/B-604/19 | | | Report Date | 10/04/2019 |

SURGICAL PATHOLOGY REPORT

Endometriotic cyst

DIAGNOSIS

ENDOMETRIOTIC CYST



SPECIMEN

Endometriotic cyst

GROSS

Received 1x1cm greyish white tissue piece.

Microscopy

- Section examined shows hemosiderin laden macrophages, fibrocollagenous issue, blood vessels, mature adipose cells. No endometrial glands and RBCs.

Note : All biopsy specimen will be stored for 15 (fifteen)days, block and slides for 5(five) years only from the time of receipt at the laboratory. No request ,for any of the above ,will be entertained after the due date.

Reference

- Rosai and Ackerman's Surgical Pathology.
- Modern Surgical Pathology.

Gulshan Yadav, MD
Consultant Pathologist