

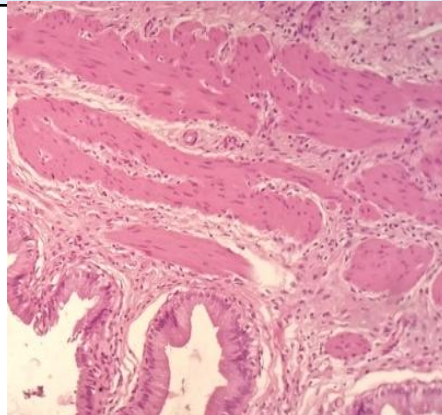
<b>Patient Name</b>	<b>Ms. HAMEEDA 836</b>	<b>Client Name</b>	Patients Care Clinical	<b>Specimen Received</b>	06/04/2019
<b>Age/Sex</b>	55 Years/Female		Laboratory, Jammu & Kashmir	<b>Specimen Type</b>	Tissue
<b>Patient ID</b>	011904060018	<b>Client Code</b>	MolQ1839P	<b>Collection Date</b>	06/04/2019
<b>Specimen ID</b>	MOLQ/B-605/19	<b>Ref. Doctor</b>		<b>Report Date</b>	09/04/2019

## SURGICAL PATHOLOGY REPORT

### Gall bladder

#### DIAGNOSIS

**CHOLECYSTITIS WITH CHOLELITHIASIS**



#### SPECIMEN

Gall bladder

#### GROSS

Received 9.1x3.2cm long gall bladder cut section shows stones.

#### Microscopy

- Section examined shows ulcerative mucosa and Rokitansky Aschoff sinus (irregularly shaped tubular structures lined by cuboidal lining epithelium with round to oval nucleus) with fibrocollagenous tissue and inflammatory cells (lymphocytes).

**Note :** All biopsy specimen will be stored for 15 (fifteen) days, block and slides for 5 (five) years only from the time of receipt at the laboratory. No request, for any of the above, will be entertained after the due date.

#### Reference

- Rosai and Ackerman's Surgical Pathology.
- Modern Surgical Pathology.

**Gulshan Yadav, MD**  
Consultant Pathologist