

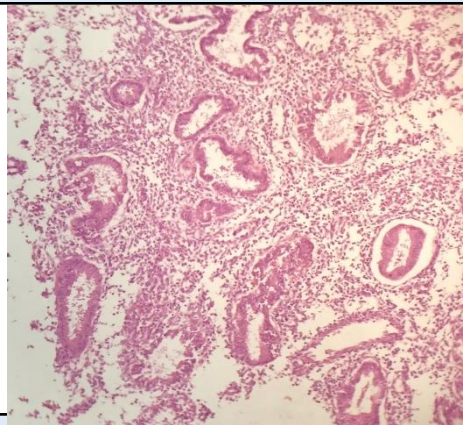
Patient Name	Mrs. VEENA	Client Name	Lifeaid Wellness Centre	Specimen Received	05/04/2019
Age/Sex	44 Years/Female	Client Code	MolQ1476CM	Specimen Type	Tissue
Patient ID	011904050496	Ref. Doctor		Collection Date	05/04/2019
Specimen ID	MOLQ/B-602/19			Report Date	09/04/2019

SURGICAL PATHOLOGY REPORT

Endometrium

DIAGNOSIS

Hyperprogestronic effect.



SPECIMEN

Endometrium

GROSS

Received multiple greyish white tissue piece.

Microscopy

Section examined shows small and tortuous endometrial glands, cuboidal lining with round nucleus with squamous metepiasia with stromal cells. No granuloma and no malignant cells seen.

Note : All biopsy specimen will be stored for 15 (fifteen)days, block and slides for 5(five) years only from the time of receipt at the laboratory. No request ,for any of the above ,will be entertained after the due date.

Reference

- i) Rosai and Ackerman's Surgical Pathology.
- ii) Modern Surgical Pathology.

**Gulshan Yadav, MD
Consultant Pathologist**