

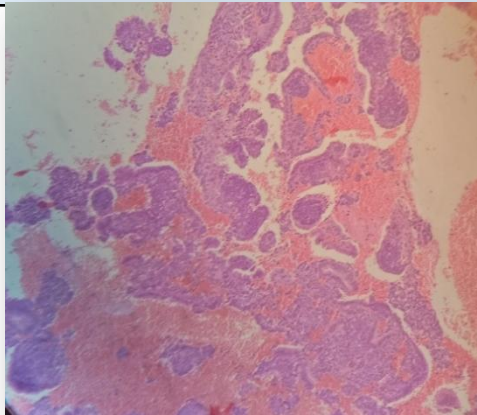
Patient Name	Ms. POONAM	Client Name	Vinayak Dental and Medical	Specimen Received	05/04/2019
Age/Sex	24 Years/Female	Centre		Specimen Type	Tissue
Patient ID	011904050040	Client Code	MolQ1860P	Collection Date	05/04/2019
Specimen ID	MOLQ/B-601/19	Ref. Doctor		Report Date	09/04/2019

SURGICAL PATHOLOGY REPORT

Endometrium

DIAGNOSIS

Disordered Proliferative phase.



SPECIMEN

Endometrium

GROSS

Received multiple greyish white tissue piece.

Microscopy

- Section examined shows small and tortuous endometrial glands with cuboidal lining epithelium with round nucleus surrounded by mononuclear inflammatory cells with RBCs.

Note : All biopsy specimen will be stored for 15 (fifteen)days, block and slides for 5(five) years only from the time of receipt at the laboratory. No request ,for any of the above ,will be entertained after the due date.

Reference

- Rosai and Ackerman's Surgical Pathology.
- Modern Surgical Pathology.

Gulshan Yadav, MD
Consultant Pathologist