

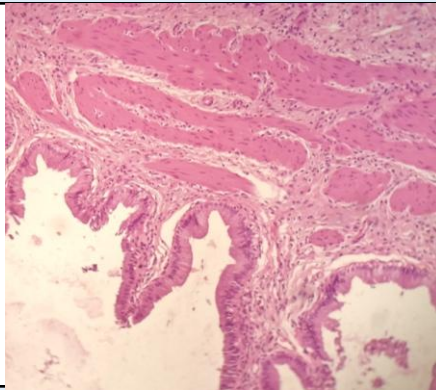
Patient Name	Mr. MUSHTAQ AHMA	Client Name	Lifeaid Wellness Centre	Specimen Received	04/04/2019
Age/Sex	51 Years/Male	Client Code	MolQ1476CM	Specimen Type	Tissue
Patient ID	011904040468	Ref. Doctor		Collection Date	04/04/2019
Specimen ID	MOLQ/B-596/19			Report Date	08/04/2019

SURGICAL PATHOLOGY REPORT

Gall bladder

DIAGNOSIS

CHOLECYSTITIS WITH CHOLELITHIASIS



SPECIMEN

Gall bladder

GROSS

Received 6.5x3.2cm long gall bladder cut section shows tiny stones.


Microscopy

- Section examined shows ulcerative mucosa and Rokitansky-Aschoff sinuses (irregularly shaped tubular structures lined by cuboidal lining epithelium with round to oval nucleus) with fibro collagenous tissue and inflammatory cells (lymphocytes).

Note : All biopsy specimen will be stored for 15 (fifteen) days, block and slides for 5 (five) years only from the time of receipt at the laboratory. No request for any of the above will be entertained after the due date.

Reference

- Rosai and Ackerman's Surgical Pathology.
- Modern Surgical Pathology.


Gulshan Yadav, MD
Consultant Pathologist