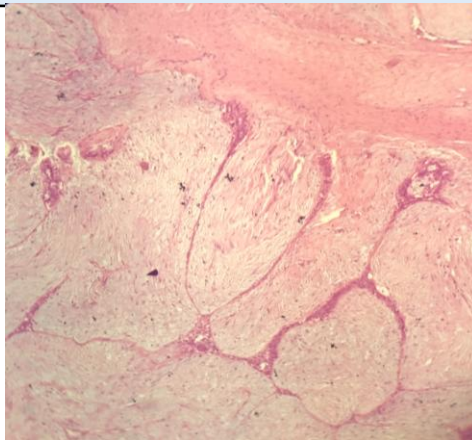


Patient Name	Mrs. MANO	Client Name	Accurate Path (C), Agra	Specimen Received	04/04/2019
Age/Sex	39 Years/Female			Specimen Type	Tissue
Patient ID	011904040079	Client Code	MolQ1671CM	Collection Date	04/04/2019
Specimen ID	MOLQ/B-592/19	Ref. Doctor	DR JYOTI GUPTA JI	Report Date	08/04/2019

SURGICAL PATHOLOGY REPORT
FIBROADENOMA

DIAGNOSIS

FIBROADENOMA



SPECIMEN
Fibroadenoma

GROSS
Received 4x3.1cm greyish white tissue piece well encapsulated.


Microscopy

1. Section examined shows cystically dilated ducts with cuboidal epithelium with small round nucleus surrounded by fibro collagenous tissue. No granuloma seen.
2. No malignant cells seen.

Note : All biopsy specimen will be stored for 15 (fifteen)days, block and slides for 5(five) years only from the time of receipt at the laboratory. No request ,for any of the above ,will be entertained after the due date.

Reference

- i) Rosai and Ackerman's Surgical Pathology.
- ii) Modern Surgical Pathology.



Gulshan Yadav, MD
Consultant Pathologist