

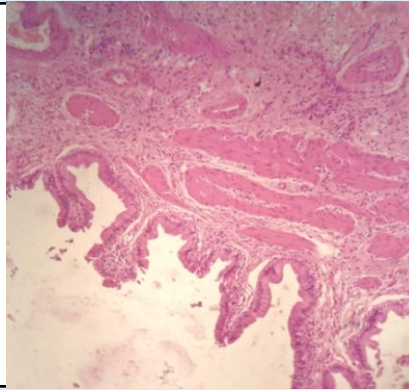
Patient Name	Mrs. MAMTA -28129	Client Name	Pushpanjali Hospital (Rewari)	Specimen Received	03/04/2019
Age/Sex	28 Years/Female	Client Code	MolQ1789CM	Specimen Type	Tissue
Patient ID	011904030459	Ref. Doctor		Collection Date	03/04/2019
Specimen ID	MOLQ/B-589/19			Report Date	08/04/2019

SURGICAL PATHOLOGY REPORT

Gall bladder

DIAGNOSIS

CHOLECYSTITIS



SPECIMEN

Gall bladder

GROSS

Received 6.1x2.3cm long gall bladder cut section shows no stone.


Microscopy

- Section examined shows ulcerative mucosa and Rokitansky-Aschoff sinuses (irregularly shaped tubular structures lined by cuboidal lining epithelium with round to oval nucleus) with fibro collagenous tissue and inflammatory cells (lymphocytes).

Note : All biopsy specimen will be stored for 15 (fifteen)days, block and slides for 5(five) years only from the time of receipt at the laboratory. No request ,for any of the above ,will be entertained after the due date.

Reference

- Rosai and Ackerman's Surgical Pathology.
- Modern Surgical Pathology.


Gulshan Yadav, MD
Consultant Pathologist