

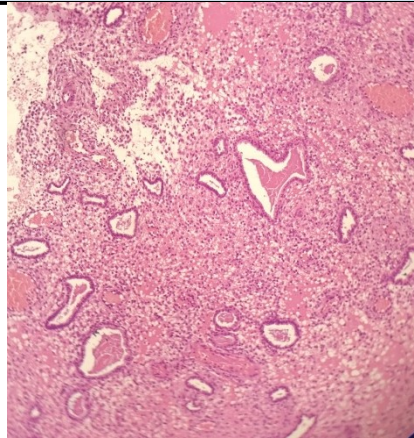
Patient Name	Mrs. PREM DEVI	Client Name	Civil Hospital-P	Specimen Received	03/04/2019
Age/Sex	40 YRS/F	Client Code		Specimen Type	Tissue
Patient ID	011904030132	Ref. Doctor		Collection Date	03/04/2019
Specimen ID	MOLQ/B-586/19			Report Date	06/04/2019

SURGICAL PATHOLOGY REPORT

Endometrium

DIAGNOSIS

Hyperprogesteric effect



SPECIMEN

Endometrium

GROSS

Received multiple greyish white tissue piece.

Microscopy

1. Section examined shows small and tortuous endometrial glands with squamous metaplasia with mononuclear inflammatory cells.
2. No granuloma and no malignant cells seen.

Note : All biopsy specimen will be stored for 15 (fifteen) days, block and slides for 5 (five) years only from the time of receipt at the laboratory. No request, for any of the above, will be entertained after the due date.

Reference

- i) Rosai and Ackerman's Surgical Pathology.
- ii) Modern Surgical Pathology.

A handwritten signature in black ink, appearing to read 'Gulshan', written over a light blue rectangular background.

Gulshan Yadav, MD
Consultant Pathologist