

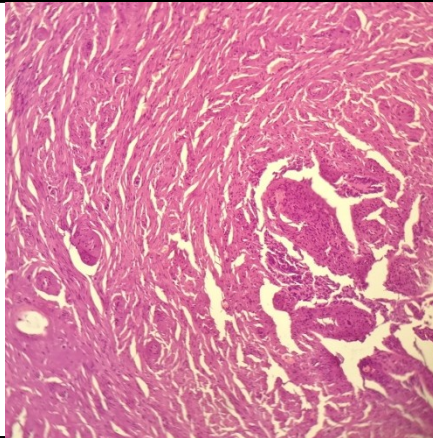
Patient Name	Mr. MEWARAM	Client Name	Galaxy Hospital, Palwal	Specimen Received	02/04/2019
Age/Sex	42 Years/male	Client Code	MolQ1890P	Specimen Type	Tissue
Patient ID	011904020294	Ref. Doctor		Collection Date	02/04/2019
Specimen ID	MOLQ/B-580/19			Report Date	06/04/2019

SURGICAL PATHOLOGY REPORT

APPENDIX.

DIAGNOSIS

ACUTE APPENDICITIS



SPECIMEN

Appendix.

GROSS

Received 3.2x1.5cm greyish white tissue piece.

Microscopy

- Section examined shows lymphoid follicles with ulcerative mucosa. Deeper tissue shows inflammatory cells (polymorphs, lymphocytes and few histiocytes).

Note : All biopsy specimen will be stored for 15 (fifteen)days, block and slides for 5(five) years only from the time of receipt at the laboratory. No request ,for any of the above ,will be entertained after the due date.

Reference

- Rosai and Ackerman's Surgical Pathology.
- Modern Surgical Pathology.

Gulshan Yadav, MD
Consultant Pathologist