

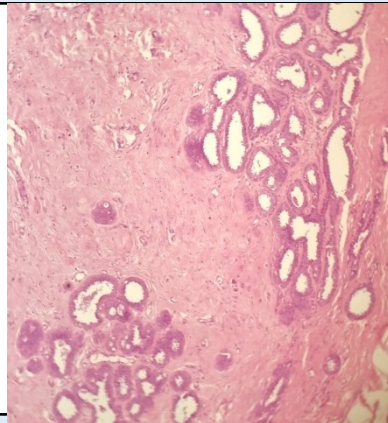
Patient Name	Miss. AISHA	Client Name	Civil Hospital-P	Specimen Received	02/04/2019
Age/Sex	20Years/Female	Client Code	MolQ1681P	Specimen Type	Tissue
Patient ID	011904020288	Ref. Doctor		Collection Date	02/04/2019
Specimen ID	MOLQ/B-579/19			Report Date	06/04/2019

SURGICAL PATHOLOGY REPORT

Breast Fibroadenoma

DIAGNOSIS

Benign breast lesion.



SPECIMEN

Breast Fibroadenoma

GROSS

Received 5x4.5cm greyish white tissue piece.

Microscopy

- Section examined shows cystically dilated ducts with cuboidal epithelium with small round nucleus surrounded by fibro collagenous tissue.

No granuloma seen. No malignant cells seen.

Note : All biopsy specimen will be stored for 15 (fifteen)days, block and slides for 5(five) years only from the time of receipt at the laboratory. No request ,for any of the above ,will be entertained after the due date.

Reference

- Rosai and Ackerman's Surgical Pathology.
- Modern Surgical Pathology.

**Gulshan Yadav, MD
Consultant Pathologist**