

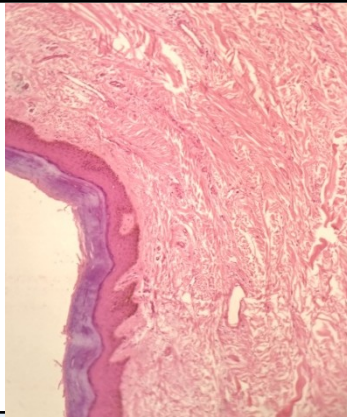
Patient Name	Mr. ASHA RAM	Client Name	Accurate Path (C), Agra	Specimen Received	31/03/19
Age/Sex	70 Years/male	Client Code	MolQ1671CM	Specimen Type	Tissue
Patient ID	011903310023	Ref. Doctor	DR RAKESH MOHANIYA MS	Collection Date	31/03/19
Specimen ID	MOLQ/B-557/19			Report Date	06/04/19

SURGICAL PATHOLOGY REPORT

Lower lump

DIAGNOSIS

Benign mesenchymal lesion.



SPECIMEN

Lower lump

GROSS

Received 2.5x1.9cm greyish white tissue piece.


Microscopy

1. Section examined shows Squamous lining epithelium with small round nucleus with mild hyperkeratosis and fibro collagenous tissue large number of blood vessels. No granuloma and no malignant cells.

Note : All biopsy specimen will be stored for 15 (fifteen)days, block and slides for 5(five) years only from the time of receipt at the laboratory. No request ,for any of the above ,will be entertained after the due date.

Reference

- i) Rosai and Ackerman's Surgical Pathology.
- ii) Modern Surgical Pathology.



Gulshan Yadav, MD
Consultant Pathologist