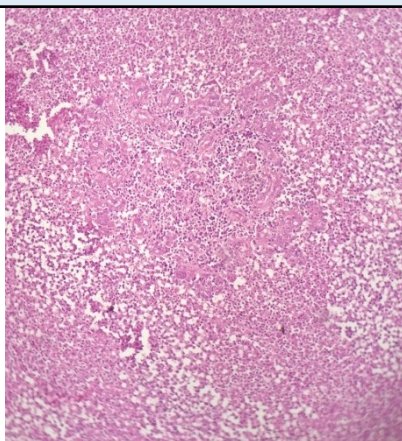


<b>Patient Name</b>	<b>Mrs. KANTA RANI</b>	<b>Client Name</b>	East India Imaging & Pathology Centre	<b>Specimen Received</b>	29/03/2019
<b>Age/Sex</b>	55 Years/Female	<b>Client Code</b>	MolQ1666CM	<b>Specimen Type</b>	Tissue
<b>Patient ID</b>	011903290085			<b>Collection Date</b>	29/03/2019
<b>Specimen ID</b>	MOLQ/B-536/19			<b>Report Date</b>	06/04/2019

## SURGICAL PATHOLOGY REPORT

Tubo ovarian mass.

### Chronic Inflammation



#### **SPECIMEN**

Tubo ovarian mass.

#### **GROSS**

Received 4.9x3.4cm greyish white tissue piece cut section shows necrotic cheese material.

#### **Microscopy**

1. Section examined shows ovarian stromal cells with ovarian tissue with large nucleus of lymphocyte, plasma cells.
2. No granuloma and no malignant cells seen.

**Note :** All biopsy specimen will be stored for 15 (fifteen) days, block and slides for 5 (five) years only from the time of receipt at the laboratory. No request for any of the above, will be entertained after the due date.

#### **Reference**

- i) Rosai and Ackerman's Surgical Pathology.
- ii) Modern Surgical Pathology.

**Gulshan Yadav, MD**  
Consultant Pathologist