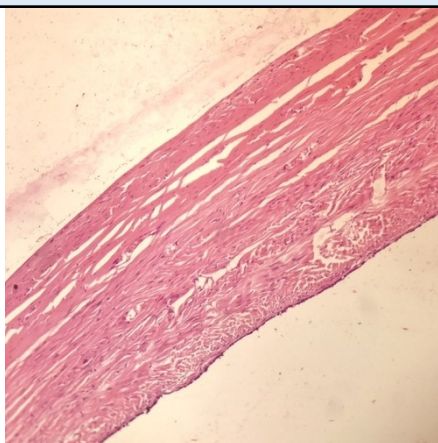


Patient Name	Mrs. KANTA RANI	Client Name	East India Imaging & Pathology Centre	Specimen Received	29/03/2019
Age/Sex	55 Years/Female	Client Code	MolQ1666CM	Specimen Type	Tissue
Patient ID	011903290085			Collection Date	29/03/2019
Specimen ID	MOLQ/B-535/19			Report Date	05/04/2019

SURGICAL PATHOLOGY REPORT

Ovary (Left) Cyst

SIMPLE CYST



SPECIMEN

Ovary (Left) Cyst

GROSS

Received 7x4.3 cm cystic tissue piece multiloculated. Cut section shows clear fluid form 1 locule and brown colored from other.

Microscopy

1. Section examined shows cuboidal lining epithelium and surrounding fibrocollagenous tissue.
2. No malignant cells and no granuloma seen.

Note : All biopsy specimen will be stored for 15 (fifteen) days, block and slides for 5 (five) years only from the time of receipt at the laboratory. No request for any of the above, will be entertained after the due date.

Reference

- i) Rosai and Ackerman's Surgical Pathology.
- ii) Modern Surgical Pathology.

Gulshan Yadav, MD
Consultant Pathologist