

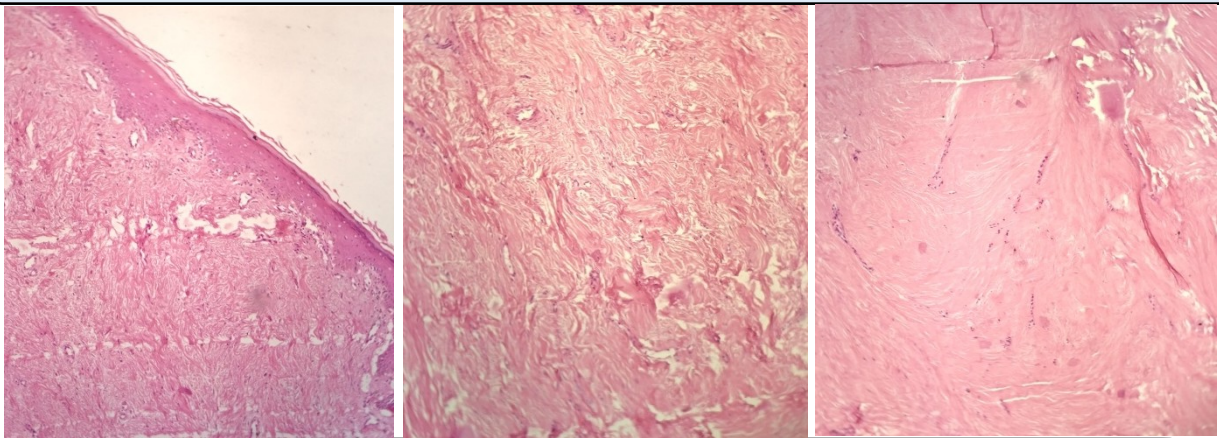
Patient Name	Mr. KISHOR JHA	Client Name	Civil Hospital-P, Gurgaon	Specimen Received	02-Apr-2019
Age/Sex	35/Male	Client Code	MolQ1681P	Specimen Type	Tissue
Patient ID	011904020236	Ref. Doctor		Collection Date	02-Apr-2019
Specimen ID	MOLQ/B-578-19			Report Date	05-Apr-2019

SURGICAL PATHOLOGY REPORT

Mouth Specimen

DIAGNOSIS

ORAL FIBROMA



SPECIMEN

Mouth Specimen

GROSS

Received 1x1cm lobulated greyish white tissue piece.

Microscopy

Scanner View reveals one bit of tissue with epithelium and connective tissue stroma.

Low Power View reveals atrophic to hyperplastic stratified squamous lining epithelium with flat interphase to long and slender rete peg formation overlying the connective tissue stroma. Connective tissue stroma reveals bundles of collagen fibers interspersed with fibrocytes.

High Power View confirms the above mentioned findings.

Note : All biopsy specimen will be stored for 15 (fifteen)days, block and slides for 5(five) years only from the time of receipt at the laboratory. No request ,for any of the above ,will be entertained after the due date.

Reference

- i) Rosai and Ackerman's Surgical Pathology.
- ii) Modern Surgical Pathology.
- iii) Shafers 7th edition

Tina Bhardwaj, MDS
Consultant Oral Histopathologist

Gulshan Yadav, MD
Consultant Pathologist