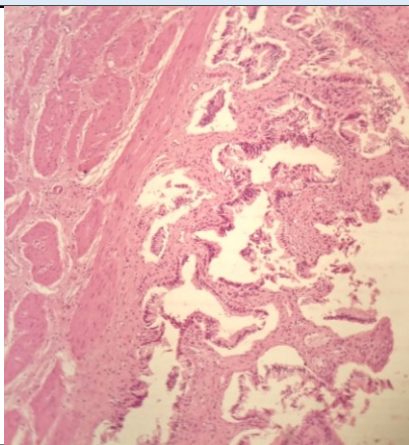


<b>Patient Name</b>	<b>Ms. DURGESH DEVI</b>	<b>Client Name</b>	Accurate Path (C), Agra	<b>Specimen Received</b>	01/04/2019
<b>Age/Sex</b>	22 Years/Female	<b>Client Code</b>	MolQ1671CM	<b>Specimen Type</b>	Tissue
<b>Patient ID</b>	011904020025	<b>Ordering Physician</b>	DR.H B GUPTA JI	<b>Collection Date</b>	01/04/2019
<b>Specimen ID</b>	MOLQ/B-576/19			<b>Report Date</b>	05/04/2019

## SURGICAL PATHOLOGY REPORT

Gall bladder

### CHOLECYSTITIS WITH CHOLELITHIASIS



#### SPECIMEN

Gall bladder

#### GROSS

Received 5x3cm long gall bladder cut section shows stones.

#### Microscopy

- Section examined shows ulcerative mucosa and Rokitansky-Aschoff sinuses (irregularly shaped tubular structures lined by cuboidal lining epithelium with round to oval nucleus) with fibro collagenous tissue and inflammatory cells (lymphocytes).

**Note :** All biopsy specimen will be stored for 15 (fifteen) days, block and slides for 5 (five) years only from the time of receipt at the laboratory. No request for any of the above, will be entertained after the due date.

#### Reference

- Rosai and Ackerman's Surgical Pathology.
- Modern Surgical Pathology.

**Gulshan Yadav, MD**  
Consultant Pathologist