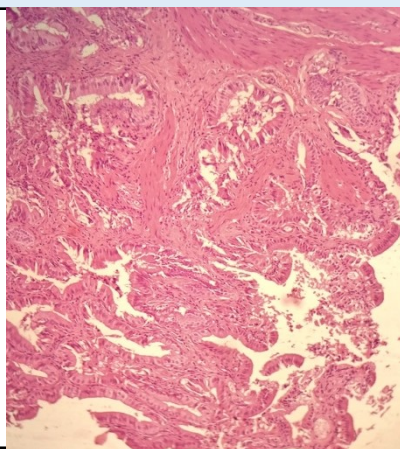


Patient Name	SUMITRA (27768)	Client Name	Pushpanjali Hospital (Rewari)	Specimen Received	31/03/2019
Age/Sex	56 YRS/F	Client Code		Specimen Type	Tissue
Patient ID	011903310379			Collection Date	31/03/2019
Specimen ID	MOLQ/B-568/19			Report Date	05/04/2019

SURGICAL PATHOLOGY REPORT

Gall bladder

CHOLECYSTITIS



SPECIMEN

Gall bladder

GROSS

Received 4.2x2.2cm long gall bladder Cut section show no stones.

Microscopy

- Section examined shows ulcerative mucosa and Rokitansky-Aschoff sinus (irregularly shaped tubular structures lined by cuboidal lining epithelium with round to oval nucleus) with fibrocollagenous tissue and inflammatory cells (lymphocytes).

Note : All biopsy specimen will be stored for 15 (fifteen) days, block and slides for 5 (five) years only from the time of receipt at the laboratory. No request for any of the above, will be entertained after the due date.

Reference

- Rosai and Ackerman's Surgical Pathology.
- Modern Surgical Pathology.

Gulshan Yadav, MD
Consultant Pathologist