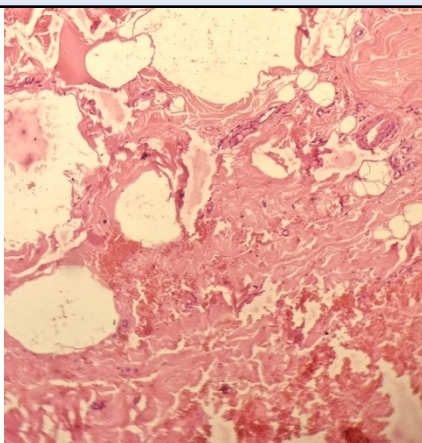


|                     |               |                    |                               |                          |            |
|---------------------|---------------|--------------------|-------------------------------|--------------------------|------------|
| <b>Patient Name</b> | NEELAM 27846  | <b>Client Name</b> | Pushpanjali Hospital (Rewari) | <b>Specimen Received</b> | 31/03/2019 |
| <b>Age/Sex</b>      | 30 YRS/F      | <b>Client Code</b> |                               | <b>Specimen Type</b>     | Tissue     |
| <b>Patient ID</b>   | 011903310377  |                    |                               | <b>Collection Date</b>   | 31/03/2019 |
| <b>Specimen ID</b>  | MOLQ/B-567/19 |                    |                               | <b>Report Date</b>       | 05/04/2019 |

## SURGICAL PATHOLOGY REPORT

### Sebaceous cyst

**Sebaceous cyst.**



#### **SPECIMEN**

Sebaceous cyst

#### **GROSS**

Received 2.5x1cm greyish white tissue piece.

#### **Microscopy**

Section examined shows Squamous lining epithelium with fibrocollagenous tissue , keratin flakes and adipose cells.

**Note :** All biopsy specimen will be stored for 15 (fifteen) days, block and slides for 5 (five) years only from the time of receipt at the laboratory. No request for any of the above, will be entertained after the due date.

#### **Reference**

- i) Rosai and Ackerman's Surgical Pathology.
- ii) Modern Surgical Pathology.

**Gulshan Yadav, MD**  
Consultant Pathologist