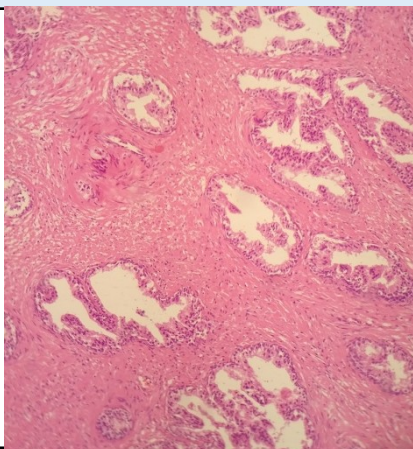


<b>Patient Name</b>	JASWANT 27769	<b>Client Name</b>	Pushpanjali Hospital (Rewari)	<b>Specimen Received</b>	31/03/2019
<b>Age/Sex</b>	60 Years/male	<b>Client Code</b>		<b>Specimen Type</b>	Tissue
<b>Patient ID</b>	011903310368			<b>Collection Date</b>	31/03/2019
<b>Specimen ID</b>	MOLQ/B-566/19			<b>Report Date</b>	05/04/2019

## SURGICAL PATHOLOGY REPORT

TURP chips

### BENIGN PROSTATIC HYPERPLASIA.



**SPECIMEN**  
TURP chips

**GROSS**  
Received multiple greyish white tissue piece 4x5cm in aggregate .

#### Microscopy

- Section examined shows bilayered prostatic glands with columnar lining epithelium and with small round to oval nucleus surrounded by large number of fibrocollagenous tissue and mononuclear inflammatory cell.

**Note :** All biopsy specimen will be stored for 15 (fifteen) days, block and slides for 5 (five) years only from the time of receipt at the laboratory. No request for any of the above, will be entertained after the due date.

#### Reference

- Rosai and Ackerman's Surgical Pathology.
- Modern Surgical Pathology.

**Gulshan Yadav, MD**  
Consultant Pathologist