

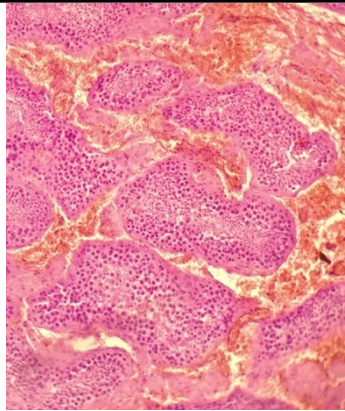
<b>Patient Name</b>	Mrs. JAVITA DEVI	<b>Client Name</b>	Accurate Path (C), Agra	<b>Specimen Received</b>	31/03/2019
<b>Age/Sex</b>	24 Years/Female	<b>Client Code</b>	MolQ1671CM	<b>Specimen Type</b>	Tissue
<b>Patient ID</b>	011903310030	<b>Ref. Doctor</b>		<b>Collection Date</b>	31/03/2019
<b>Specimen ID</b>	MOLQ/B-558/19			<b>Report Date</b>	04/04/2019

## SURGICAL PATHOLOGY REPORT

### Vesicular mode

#### DIAGNOSIS

**Molar pregnancy**



#### SPECIMEN

Vesicular mode

#### GROSS

Received 4.8x4.2cm greyish white tissue piece in aggregate.


#### Microscopy

1. Section examined shows trophoblastic cells with hydropic changes. No villi seen.

**Note :** All biopsy specimen will be stored for 15 (fifteen)days, block and slides for 5(five) years only from the time of receipt at the laboratory. No request ,for any of the above ,will be entertained after the due date.

#### Reference

- i) Rosai and Ackerman's Surgical Pathology.
- ii) Modern Surgical Pathology.



**Gulshan Yadav, MD**  
Consultant Pathologist