

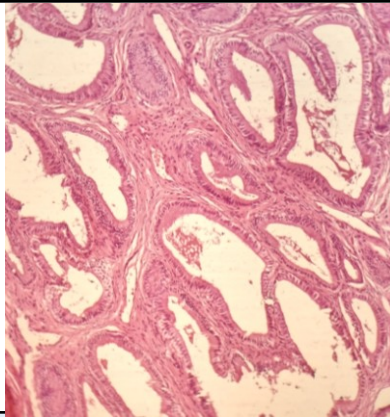
Patient Name	Mrs. DILSHADA	Client Name	A-One Collection Centre,	Specimen Received	31/03/2019
Age/Sex	37 Years/Female		Jammu & Kashmir	Specimen Type	Tissue
Patient ID	041903300011	Client Code	MolQ1833P	Collection Date	31/03/2019
Specimen ID	MOLQ/B-562/19	Ref. Doctor		Report Date	04/04/2019

SURGICAL PATHOLOGY REPORT

GALL BLADDER.

DIAGNOSIS

CHOLECYSTITIS AND CHOLELITHIASIS



SPECIMEN

Gall Bladder.

GROSS

Received 6.5x3 cm long gall bladder. Cut section shows stones.

Microscopy

1. Section examined shows ulcerative mucosa and Rokitansky Aschoff sinus (irregularly shaped tubular structures lined by cuboidal lining epithelium with round to oval nucleus) with fibro collagenous tissue and inflammatory cells (lymphocytes).

Note : All biopsy specimen will be stored for 15 (fifteen)days, block and slides for 5(five) years only from the time of receipt at the laboratory. No request ,for any of the above ,will be entertained after the due date.

Reference

- i) Rosai and Ackerman's Surgical Pathology.
- ii) Modern Surgical Pathology.

**Gulshan Yadav, MD
Consultant Pathologist**