

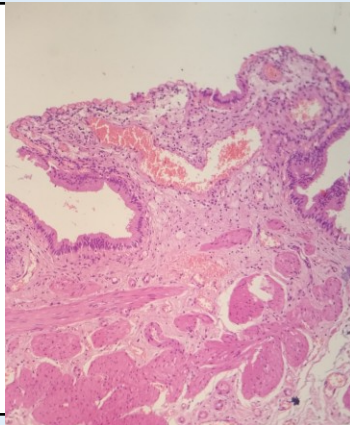
Patient Name	Mrs. BEENA	Client Name	Ashtha Path Lab-B	Specimen Received	31/03/2019
Age/Sex	40 Years/Female	Client Code		Specimen Type	Tissue
Patient ID	011903310328	Ref. Doctor		Collection Date	31/03/2019
Specimen ID	MOLQ/B-565/19			Report Date	04/04/2019

SURGICAL PATHOLOGY REPORT

GALL BLADDER

DIAGNOSIS

ACUTE CHOLECYSTITIS



SPECIMEN

Gall Bladder.

GROSS

Received 9x2.4cm long gall bladder cut section shows no stones.

Microscopy

1. Section examined shows ulcerative mucosa and Rokitansky Aschoff sinus (irregularly shaped tubular structures lined by cuboidal lining epithelium with round to oval nucleus) with fibro collagenous tissue and inflammatory cells (lymphocytes, polymorphs).

Note : All biopsy specimen will be stored for 15 (fifteen)days, block and slides for 5(five) years only from the time of receipt at the laboratory. No request ,for any of the above ,will be entertained after the due date.

Reference

- i) Rosai and Ackerman's Surgical Pathology.
- ii) Modern Surgical Pathology.

**Gulshan Yadav, MD
Consultant Pathologist**