

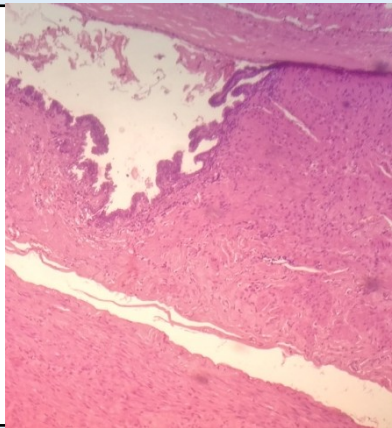
Patient Name	Ms. AFROOZA ANG	Client Name	Patients Care Clinical	Specimen Received	30/03/2019
Age/Sex	40 Years/Female		Laboratory, Jammu & Kashmir	Specimen Type	Tissue
Patient ID	011903300351	Client Code	MolQ1839P	Collection Date	30/03/2019
Specimen ID	MOLQ/B-555/19	Ref. Doctor	WANIS HOSPITAL	Report Date	04/04/2019

SURGICAL PATHOLOGY REPORT

Left Ovarian Dermoid Cyst

DIAGNOSIS

DERMOID CYST



SPECIMEN

Left Ovarian Dermoid Cyst.

GROSS

Received 4.5x3.6 cm cystic tissue piece, cut section shows cheesy material and hair.

Microscopy

Section examined shows lining epithelium with round to oval nucleus, fibrocollagenous tissue, adipose cells, blood vessels, fibrocollagenous tissue and sebaceous glands.

No granuloma and no malignant cells seen.

Note : All biopsy specimen will be stored for 15 (fifteen)days, block and slides for 5(five) years only from the time of receipt at the laboratory. No request ,for any of the above ,will be entertained after the due date.

Reference

- i) Rosai and Ackerman's Surgical Pathology.
- ii) Modern Surgical Pathology.

Gulshan Yadav, MD
Consultant Pathologist