

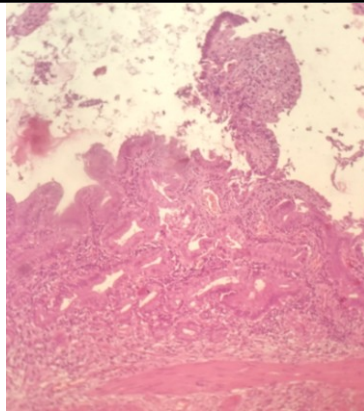
<b>Patient Name</b>	<b>Mr. NISAR AH / RUHQ</b>	<b>Client Name</b>	Patients Care Clinical	<b>Specimen Received</b>	30/03/2019
<b>Age/Sex</b>	52 Years/Male		Laboratory, Jammu & Kashmir	<b>Specimen Type</b>	Tissue
<b>Patient ID</b>	011903300350	<b>Client Code</b>	MolQ1839P	<b>Collection Date</b>	30/03/2019
<b>Specimen ID</b>	MOLQ/B-554/19	<b>Ref. Doctor</b>	PATIENTS CARE	<b>Report Date</b>	04/04/2019

## SURGICAL PATHOLOGY REPORT

### GALL BLADDER.

#### DIAGNOSIS

**CHOLECYSTITIS AND CHOLELITHIASIS**



#### SPECIMEN

Gall Bladder.

#### GROSS

Received 6.8x2.7 cm long gall bladder. Cut section shows stones.

#### Microscopy

- Section examined shows ulcerative mucosa and Rokitansky Aschoff sinus (irregularly shaped tubular structures lined by cuboidal lining epithelium with round to oval nucleus) with fibrocollagenous tissue and inflammatory cells (lymphocytes).

**Note :** All biopsy specimen will be stored for 15 (fifteen) days, block and slides for 5 (five) years only from the time of receipt at the laboratory. No request, for any of the above, will be entertained after the due date.

#### Reference

- Rosai and Ackerman's Surgical Pathology.
- Modern Surgical Pathology.

**Gulshan Yadav, MD**  
Consultant Pathologist