

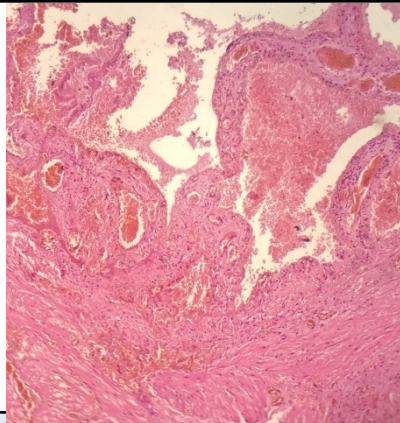
Patient Name	MRS SUGRA	Client Name	New Unique Diagnostic Center,	Specimen Received	29/03/2019
Age/Sex	32 Years/Female		Jammu & Kashmir	Specimen Type	Tissue
Patient ID	011903280169	Client Code	MolQ1833P	Collection Date	29/03/2019
Specimen ID	MOLQ/B-563/19	Ref. Doctor	DR ISHTIYAQ AHMAD	Report Date	04/04/2019

SURGICAL PATHOLOGY REPORT

GALL BLADDER.

DIAGNOSIS

CHOLECYSTITIS



SPECIMEN

Gall Bladder.

GROSS

Received 4.1x3.3 cm long gall bladder. Cut section shows no stones.

Microscopy

- Section examined shows ulcerative mucosa and Rokitansky Aschoff sinus (irregularly shaped tubular structures lined by cuboidal lining epithelium with round to oval nucleus) with fibro collagenous tissue and inflammatory cells (lymphocytes).

Note : All biopsy specimen will be stored for 15 (fifteen) days, block and slides for 5 (five) years only from the time of receipt at the laboratory. No request, for any of the above, will be entertained after the due date.

Reference

- Rosai and Ackerman's Surgical Pathology.
- Modern Surgical Pathology.

Gulshan Yadav, MD
Consultant Pathologist