

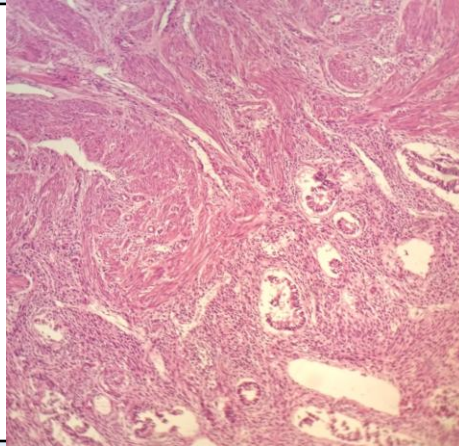
Patient Name	Ms. VIDHYA 27585	Client Name	Pushpanjali Hospital (Rewari)	Specimen Received	29/03/2019
Age/Sex	39Years/Female	Client Code		Specimen Type	Tissue
Patient ID	011903290401	Ref. Doctor		Collection Date	29/03/2019
Specimen ID	MOLQ/B-542/19			Report Date	03/04/2019

SURGICAL PATHOLOGY REPORT

Uterus

DIAGNOSIS

CHORNIC CERVICITIS WITH ENDOMETRIAL POLYP



SPECIMEN

Uterus

GROSS

Received 9.4x6.4 cm long uterus with cervix with bilateral tubes. Cut section shows endometrial polyp measuring 2.5x5 cm.

Microscopy

Section examined shows

1. Endometrium with proliferative phase
2. Myometrium with muscle bundles
3. Cervix with mononuclear inflammatory cells
4. Polyp with endometrial glands and stromal cells
5. Tubes- Bilateral confirmed and unremarkable

Note : All biopsy specimen will be stored for 15 (fifteen) days, block and slides for 5 (five) years only from the time of receipt at the laboratory. No request, for any of the above, will be entertained after the due date.

Reference

- i) Rosai and Ackerman's Surgical Pathology.
- ii) Modern Surgical Pathology. *Report generated at MolQ Laboratory, Gurgaon*

Gulshan Yadav, MD
Consultant Pathologist