

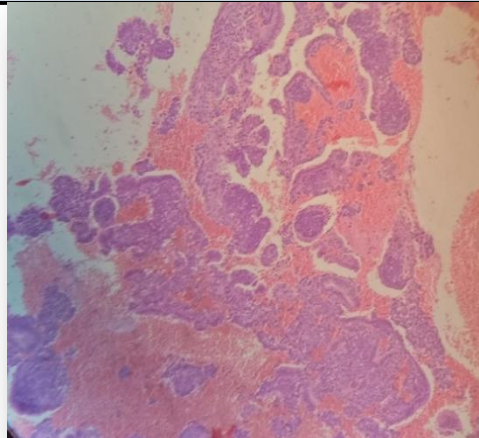
| | | | | | |
|---------------------|---------------------------|--------------------|------------------------|--------------------------|------------|
| Patient Name | FEHMEEDA /KHAHGUND | Client Name | Patients Care Clinical | Specimen Received | 30/03/2019 |
| Age/Sex | 45 Years/Female | | Laboratory, J& K | Specimen Type | Tissue |
| Patient ID | 011903300349 | Client Code | MolQ1839P | Collection Date | 30/03/2019 |
| Specimen ID | MOLQ/B-553/19 | Ref. Doctor | CARE DIAG | Report Date | 02/04/2019 |

SURGICAL PATHOLOGY REPORT

Endometrium

DIAGNOSIS

PROLIFERATIVE PHASE



SPECIMEN

Endometrium

GROSS

Received multiple tiny greyish white tissue piece.

Microscopy

- Section examined shows small endometrial glands with columnar lining epithelium with round to oval nucleus. Stroma shows mononuclear inflammatory cells and RBCs.
- No malignant cells and no granuloma seen.

Note : All biopsy specimen will be stored for 15 (fifteen)days, block and slides for 5(five) years only from the time of receipt at the laboratory. No request ,for any of the above ,will be entertained after the due date.

Reference

- Rosai and Ackerman's Surgical Pathology.
- Modern Surgical Pathology.

Gulshan Yadav, MD
Consultant Pathologist