

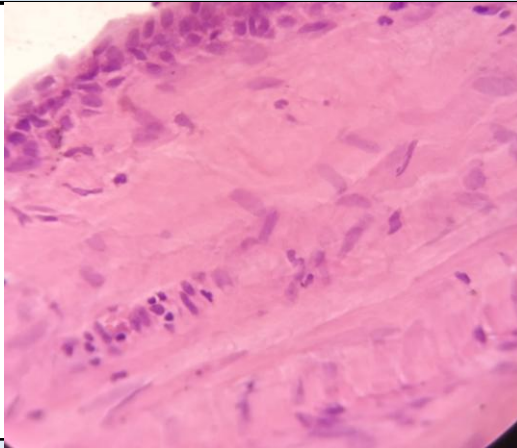
Patient Name	Mrs. SEEMA YADAV	Client Name	Civil Hospital-P	Specimen Received	30/03/2019
Age/Sex	27 Years/Female	Client Code	MolQ1681P	Specimen Type	Tissue
Patient ID	011903300273	Ref. Doctor		Collection Date	30/03/2019
Specimen ID	MOLQ/B-549/19			Report Date	02/04/2019

SURGICAL PATHOLOGY REPORT

Ovarian Cyst

DIAGNOSIS

DERMOID CYST



SPECIMEN

Ovarian Cyst

GROSS

Received 13.5x7.9 cm cystic tissue piece. Cut section shows multiloculations with straw colored fluid with cheezy material and hair.

Microscopy

- Section examined shows keratin flakes, epithelial lining with round to oval nucleus, fibrocollagenous tissue and bits of hair in the lumen and blood vessels. No granuloma seen. No malignant cells seen.

Note : All biopsy specimen will be stored for 15 (fifteen) days, block and slides for 5 (five) years only from the time of receipt at the laboratory. No request ,for any of the above ,will be entertained after the due date.

Reference

- Rosai and Ackerman's Surgical Pathology.
- Modern Surgical Pathology.

Gulshan Yadav, MD
Consultant Pathologist