

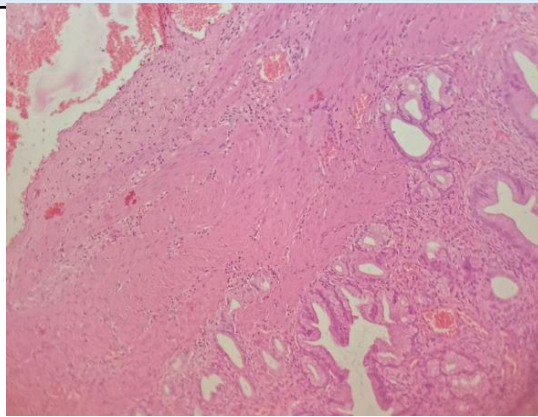
<b>Patient Name</b>	SHANTI DEVI	<b>Client Name</b>	Civil Hospital-P	<b>Specimen Received</b>	30/03/2019
<b>Age/Sex</b>	25 YRS/F	<b>Client Code</b>	MolQ1839P	<b>Specimen Type</b>	Tissue
<b>Patient ID</b>	011903300221	<b>Ref. Doctor</b>		<b>Collection Date</b>	30/03/2019
<b>Specimen ID</b>	MOLQ/B-548/19			<b>Report Date</b>	02/04/2019

**SURGICAL PATHOLOGY REPORT**

**GALL BLADDER.**

**DIAGNOSIS**

**CHOLECYSTITIS AND CHOLELITHIASIS**



**SPECIMEN**

Gall Bladder.

**GROSS**

Received 4.2x2.1 cm long gall bladder. Cut section shows tiny stones.

**Microscopy**

1. Section examined shows ulcerative mucosa and Rokitansky-Aschoff sinuses (irregularly shaped tubular structures lined by cuboidal lining epithelium with round to oval nucleus) with fibro collagenous tissue and inflammatory cells (lymphocytes).

**Note :** All biopsy specimen will be stored for 15 (fifteen) days, block and slides for 5 (five) years only from the time of receipt at the laboratory. No request ,for any of the above ,will be entertained after the due date.

**Reference**

- i) Rosai and Ackerman's Surgical Pathology.
- ii) Modern Surgical Pathology.

**Gulshan Yadav, MD  
Consultant Pathologist**