

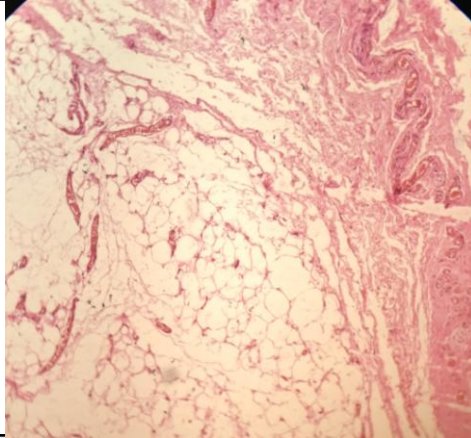
Patient Name	Mrs. VASUMATI MUPPIDI	Client Name	MolQ CC Greenleaf Diagnostic	Specimen Received	30/03/2019
Age/Sex	64 Years/Female	Client Code	MolQ1851CM	Specimen Type	Tissue
Patient ID	011903300210	Ref. Doctor		Collection Date	30/03/2019
Specimen ID	MOLQ/B-547/19			Report Date	02/04/2019

SURGICAL PATHOLOGY REPORT

Left Thumb Lump

DIAGNOSIS

LIPOMA



SPECIMEN

Left Thumb Lump

GROSS

Received 3.2x2.6 cm lobulated greyish tissue piece, cut section shows yellowish mass.

Microscopy

Section examined shows mature adipose cells with fibocollagenous tissue and few inflammatory cells.

No malignant and no granuloma seen.

Note : All biopsy specimen will be stored for 15 (fifteen) days, block and slides for 5 (five) years only from the time of receipt at the laboratory. No request, for any of the above, will be entertained after the due date.

Reference

- i) Rosai and Ackerman's Surgical Pathology.
- ii) Modern Surgical Pathology.

Gulshan Yadav, MD
Consultant Pathologist