

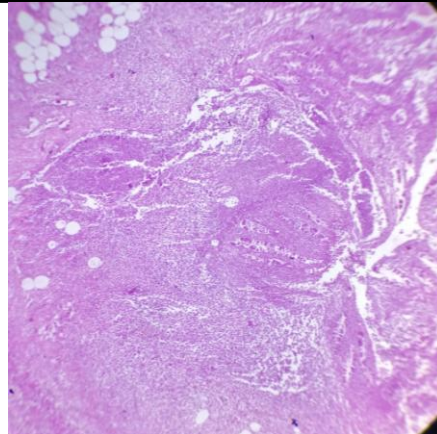
Patient Name	Mrs. SARSWATI	Client Name	Civil Hospital-P	Specimen Received	29/03/2019
Age/Sex	27 Years/Female	Client Code	MolQ1681P	Specimen Type	Tissue
Patient ID	011903290315	Ref. Doctor		Collection Date	29/03/2019
Specimen ID	MOLQ/B-539/19			Report Date	02/03/2019

SURGICAL PATHOLOGY REPORT

APPENDIX.

DIAGNOSIS

ACUTE APPENDICITIS



SPECIMEN

Appendix.

GROSS

Received 4.9x2.0 cm long appendix with attached fat.

Microscopy

- Section examined shows lymphoid follicles with ulcerative mucosa. Deeper tissue shows inflammatory cells (polymorphs and lymphocytes).

Note : All biopsy specimen will be stored for 15 (fifteen) days, block and slides for 5 (five) years only from the time of receipt at the laboratory. No request, for any of the above, will be entertained after the due date.

Reference

- Rosai and Ackerman's Surgical Pathology.
- Modern Surgical Pathology.

Gulshan Yadav, MD
Consultant Pathologist