

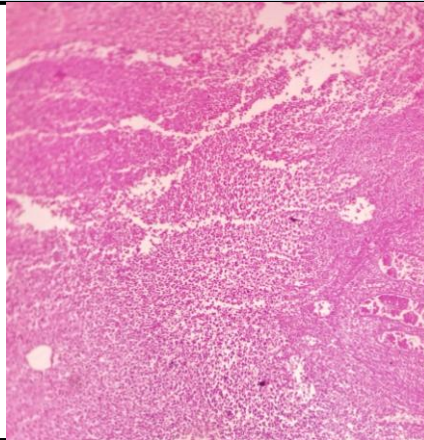
| | | | | | |
|---------------------|----------------------|--------------------|------------------|--------------------------|------------|
| Patient Name | Mrs. SARSWATI | Client Name | Civil Hospital-P | Specimen Received | 29/03/2019 |
| Age/Sex | 27 Years/Female | Client Code | MolQ1681P | Specimen Type | Tissue |
| Patient ID | 011903290315 | Ref. Doctor | | Collection Date | 29/03/2019 |
| Specimen ID | MOLQ/B-539/19 | | | Report Date | 02/03/2019 |

SURGICAL PATHOLOGY REPORT

APPENDIX.

DIAGNOSIS

ACUTE APPENDICITIS



SPECIMEN

Appendix.

GROSS

Received 4.9x2.0 cm long appendix with attached fat.

Microscopy

- Section examined shows lymphoid follicles with ulcerative mucosa. Deeper tissue shows inflammatory cells (polymorphs and lymphocytes).

Note : All biopsy specimen will be stored for 15 (fifteen) days, block and slides for 5 (five) years only from the time of receipt at the laboratory. No request, for any of the above, will be entertained after the due date.

Reference

- Rosai and Ackerman's Surgical Pathology.
- Modern Surgical Pathology.

Gulshan Yadav, MD
Consultant Pathologist