

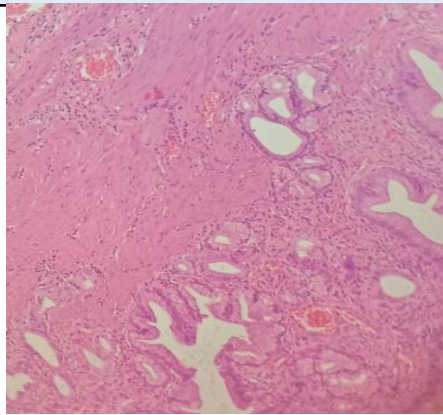
Patient Name	Mrs. ANJALI	Client Name	Civil Hospital-P	Specimen Received	28/03/2019
Age/Sex	30 Years/Female	Client Code	MolQ1681P	Specimen Type	Tissue
Patient ID	011903280113	Ref. Doctor	Dr. SAURABH	Collection Date	28/03/2019
Specimen ID	MOLQ/B-530/19			Report Date	02/03/2019

SURGICAL PATHOLOGY REPORT

GALL BLADDER.

DIAGNOSIS

CHOLECYSTITIS AND CHOLELITHIASIS



SPECIMEN

Gall Bladder.

GROSS

Received 4.7x3.1 cm long gall bladder. Cut section shows stones.

Microscopy

- Section examined shows ulcerative mucosa and Rokitansky Aschoff sinus (irregularly shaped tubular structures lined by cuboidal lining epithelium with round to oval nucleus) with fibrocollagenous tissue and inflammatory cells (lymphocytes).

Note : All biopsy specimen will be stored for 15 (fifteen) days, block and slides for 5 (five) years only from the time of receipt at the laboratory. No request, for any of the above, will be entertained after the due date.

Reference

- Rosai and Ackerman's Surgical Pathology.
- Modern Surgical Pathology.

Gulshan Yadav, MD
Consultant Pathologist