

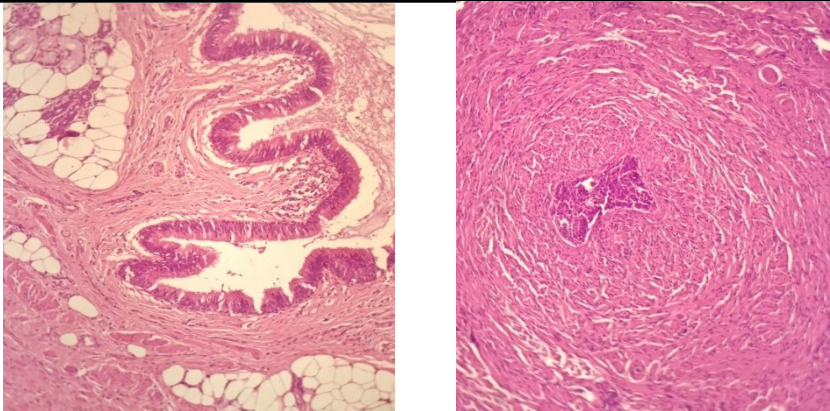
<b>Patient Name</b>	Ms. DEEPIKA	<b>Client Name</b>	Pushpanjali Hospital (Rewari)	<b>Specimen Received</b>	26/03/2019
<b>Age/Sex</b>	32 YRS/F	<b>Client Code</b>	MolQ1789CM	<b>Specimen Type</b>	Tissue
<b>Patient ID</b>	011903260493	<b>Ref. Doctor</b>		<b>Collection Date</b>	26/03/2019
<b>Specimen ID</b>	MOLQ/B-506/19 (2)			<b>Report Date</b>	30/03/2019

## SURGICAL PATHOLOGY REPORT

### Tubes (Bilateral)

#### DIAGNOSIS

- 1) Tube is confirmed and unremarkable
- 2) Kindly, co-relate with clinical findings.



#### SPECIMEN

Tubes (Bilateral)

#### GROSS

Received two tubes measuring 1x0.5 cm each in the same container.

#### Microscopy

- 1) Tube: Section examined shows tubal lining epithelium with surrounding fibrocollagenous tissue.
- 2) Tube: Section examined shows fibrocollagenous tissue.

**Note :** All biopsy specimen will be stored for 15 (fifteen)days, block and slides for 5(five) years only from the time of receipt at the laboratory. No request ,for any of the above ,will be entertained after the due date.

#### Reference

- i) Rosai and Ackerman's Surgical Pathology.
- ii) Modern Surgical Pathology.

**Gulshan Yadav, MD**  
Consultant Pathologist