

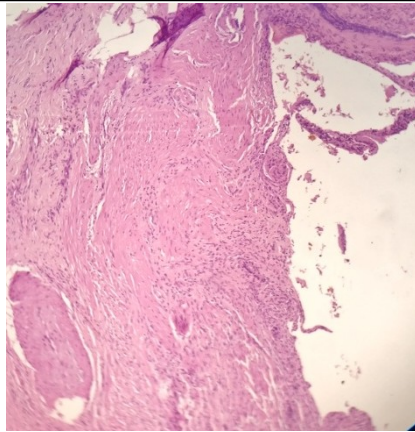
<b>Patient Name</b>	Ms. DEEPIKA-27624	<b>Client Name</b>	Pushpanjali Hospital (Rewari),	<b>Specimen Received</b>	26-Mar-2019
<b>Age/Sex</b>	32/F			<b>Specimen Type</b>	Tissue
<b>Patient ID</b>	011903260493	<b>Client Code</b>	MolQ1789CM	<b>Collection Date</b>	26-Mar-2019
<b>Specimen ID</b>	MOLQ/B-506-19 (1)	<b>Ref. Doctor</b>	DR.KIRAN	<b>Report Date</b>	30-Mar-2019

## SURGICAL PATHOLOGY REPORT

### Dermoid Cyst

#### DIAGNOSIS

#### DERMOID CYST



#### SPECIMEN

Dermoid Cyst

#### GROSS

Received autolyzed 4.8x3.9 cm cystic greyish white tissue piece. Cut section shows cheesy material

#### Microscopy

1. Section examined shows squamous lining epithelium with small round nucleus.
2. Deeper tissue shows fibrocollagenous tissue, blood vessels with few inflammatory cells.
3. No granuloma and no malignant cells seen.

**Note :** All biopsy specimen will be stored for 15 (fifteen)days, block and slides for 5(five) years only from the time of receipt at the laboratory. No request ,for any of the above ,will be entertained after the due date.

#### Reference

- i) Rosai and Ackerman's Surgical Pathology.
- ii) Modern Surgical Pathology.

**Gulshan Yadav, MD**  
Consultant Pathologist