

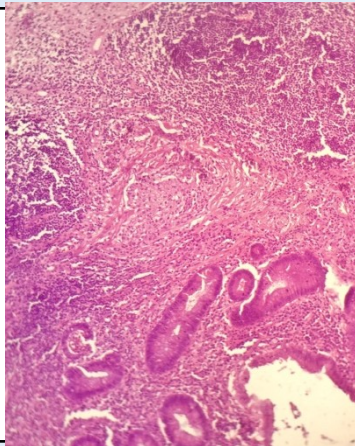
Patient Name	Ms. SHAKUNTALA	Client Name	Pushpanjali Hospital (Rewari)	Specimen Received	27-Mar-2019
Age/Sex	57/F	Client Code	MolQ1789CM	Specimen Type	Tissue
Patient ID	011903270414	Ref. Doctor	DR Kuldeep	Collection Date	27-Mar-2019
Specimen ID	MOLQ/B-521/19			Report Date	29-Mar-2019

SURGICAL PATHOLOGY REPORT

APPENDIX.

DIAGNOSIS

ACUTE APPENDICITIS.



SPECIMEN

Appendix.

GROSS

Received 6x1.1 cm long appendix with mesoappendix

Microscopy

- Section examined shows lymphoid follicles with ulcerative mucosa. Deeper tissue shows inflammatory cells (polymorphs and lymphocytes).

Note : All biopsy specimen will be stored for 15 (fifteen) days, block and slides for 5 (five) years only from the time of receipt at the laboratory. No request, for any of the above, will be entertained after the due date.

Reference

- Rosai and Ackerman's Surgical Pathology.
- Modern Surgical Pathology.

Gulshan Yadav, MD
Consultant Pathologist