

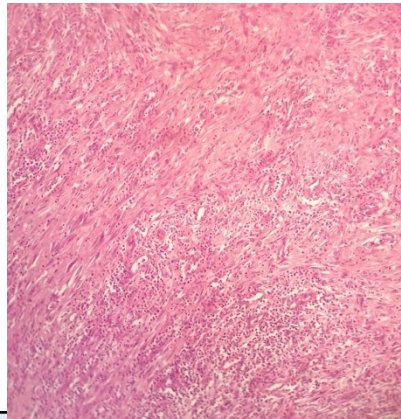
Patient Name	Mrs. SAHAJBI	Client Name	Murad Hospital, Nuh	Specimen Received	27-Mar-2019
Age/Sex	45/F	Client Code	MolQ1830P	Specimen Type	Tissue
Patient ID	011903270366	Ref. Doctor		Collection Date	27-Mar-2019
Specimen ID	MOLQ/B-519/19			Report Date	29-Mar-2019

SURGICAL PATHOLOGY REPORT

GALL BLADDER.

DIAGNOSIS

CHOLECYSTITIS



SPECIMEN

Gall Bladder.

GROSS

Received 9x2.5 cm long gall bladder with thickened wall. Cut section shows stones with lymph node measuring 1x1 cm.

Microscopy

- Section examined shows ulcerative mucosa and rokitansky aschoff sinus (irregularly shaped tubular structures lined by cuboidal lining epithelium with round to oval nucleus) with fibro collagenous tissue, calcifications and inflammatory cells (lymphocytes).
- Lymph node: Reactive

Note : All biopsy specimen will be stored for 15 (fifteen) days, block and slides for 5 (five) years only from the time of receipt at the laboratory. No request ,for any of the above will be entertained after the due date.

Reference

- Rosai and Ackerman's Surgical Pathology.
- Modern Surgical Pathology.

Gulshan Yadav, MD
Consultant Pathologist