

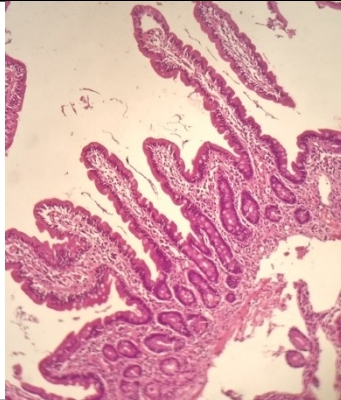
Patient Name	Mr. MUKESH JAIN	Client Name	Khan Diagnostic Centre	Specimen Received	26-Mar-2019
Age/Sex	52/M		Gurgaon	Specimen Type	Tissue
Patient ID	011903260558	Client Code	MolQ1809CM	Collection Date	26-Mar-2019
Specimen ID	MOLQ/B-505-19	Ref. Doctor	DR RAJAN	Report Date	29-Mar-2019

SURGICAL PATHOLOGY REPORT

D2 Gastrointestinal Biopsy

DIAGNOSIS

NON-SPECIFIC INFLAMMATION



SPECIMEN

D2 Gastrointestinal Biopsy

GROSS

Received multiple greyish white tissue piece.

Microscopy

Section examined shows villi lined by columnar lining epithelium and small round nucleus with submucosal glands and inflammatory cells.

No malignant cells and no granuloma seen.

Modified Marsh Classification:

<30/100 enterocytes, intraepithelial lymphocytes per 100 enterocytes.

Type 0: Normal; celiac disease highly unlikely.

Note : All biopsy specimen will be stored for 15 (fifteen)days, block and slides for 5(fiv the time of receipt at the laboratory. No request ,for any of the above ,will be entertained after the due da

Reference

- i) Rosai and Ackerman's Surgical Pathology.
- ii) Modern Surgical Pathology.

Gulshan Yadav, MD
Consultant Pathologist