

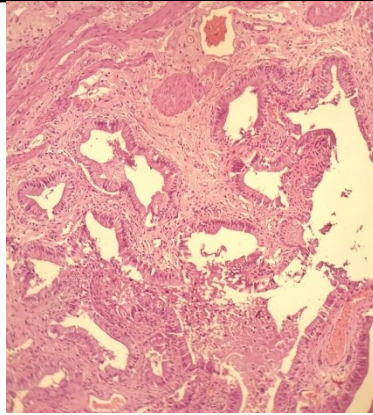
Patient Name	Ms. KAMLA 27647	Client Name	Pushpanjali Hospital (Rewari)	Specimen Received	26-Mar-2019
Age/Sex	52/F	Client Code	MolQ1789CM	Specimen Type	Tissue
Patient ID	011903260489	Ref. Doctor	Dr. KULDEEP	Collection Date	26-Mar-2019
Specimen ID	MOLQ/B-513/19			Report Date	29-Mar-2019

SURGICAL PATHOLOGY REPORT

GALL BLADDER.

DIAGNOSIS

CHOLECYSTITIS



SPECIMEN

Gall Bladder.

GROSS

Received autolyzed 6x2.7 cm long gall bladder. Cut section shows no stones.

Microscopy

1. Section examined shows ulcerative mucosa and Rokitansky-Aschoff sinuses (irregularly shaped tubular structures lined by cuboidal lining epithelium with round to oval nucleus) with fibrocollagenous tissue, calcifications and inflammatory cells (lymphocytes).

Note : All biopsy specimen will be stored for 15 (fifteen) days, block and slides for 5 (five) years only from the time of receipt at the laboratory. No request for any of the above will be entertained after the due date.

Reference

- i) Rosai and Ackerman's Surgical Pathology.
- ii) Modern Surgical Pathology.

Gulshan Yadav, MD
Consultant Pathologist