

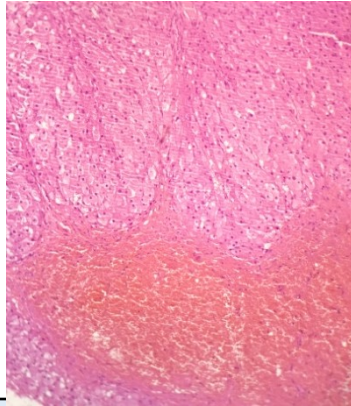
<b>Patient Name</b>	<b>Ms. FEHMEEDA /ARIN</b>	<b>Client Name</b>	Bandipora Collection Centre,	<b>Specimen Received</b>	27-Mar-2019
<b>Age/Sex</b>	38/F		Jammu & Kashmir	<b>Specimen Type</b>	Tissue
<b>Patient ID</b>	011903260280	<b>Client Code</b>	MolQ1929P	<b>Collection Date</b>	27-Mar-2019
<b>Specimen ID</b>	MOLQ/B-514-19	<b>Ref. Doctor</b>	DR ISHFAQ	<b>Report Date</b>	29-Mar-2019

## SURGICAL PATHOLOGY REPORT

### Ovarian Cyst

#### DIAGNOSIS

- 1) HEMORRHAGIC CYST
- 2) LUTEAL CYST



#### SPECIMEN

Ovarian Cyst

#### Microscopy

Section examined shows

- 1) Ovary + Tube: Section from ovary shows ovarian tissue with blood clot and tube unremarkable.
- 2) Other ovary + Tube: Section from ovary shows ovarian tissue with luteal cyst and tube unremarkable.

**Note :** All biopsy specimen will be stored for 15 (fifteen) days, block and slides for 5 (five) years only from the time of receipt at the laboratory. No request, for any of the above, will be entertained after the due date.

#### GROSS

Received two ovaries with attached tubes in the same container measuring 1) Ovary 3.5x3.2cm, cut section shows blood clot 2) Other ovary 2.5x3.5 cm with attached fat.

#### Reference

- i) Rosai and Ackerman's Surgical Pathology.
- ii) Modern Surgical Pathology.

A handwritten signature in black ink, appearing to read 'Gulshan', written over a light blue rectangular background.

**Gulshan Yadav, MD**  
**Consultant Pathologist**