

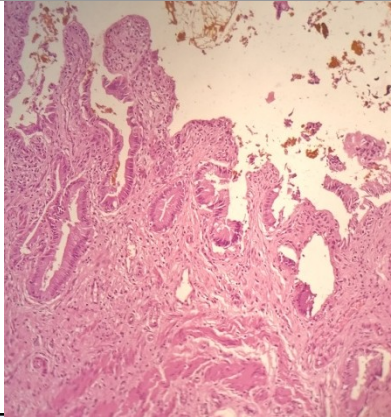
<b>Patient Name</b>	<b>Mrs. NEERAJ</b>	<b>Client Name</b>	Shri Balaji Multispeciality	<b>Specimen Received</b>	26-Mar-2019
<b>Age/Sex</b>	28/F		Hospital-Gurgaon	<b>Specimen Type</b>	Tissue
<b>Patient ID</b>	011903260213	<b>Client Code</b>	MolQ1269CM	<b>Collection Date</b>	26-Mar-2019
<b>Specimen ID</b>	MOLQ/B-510/19	<b>Ref. Doctor</b>		<b>Report Date</b>	29-Mar-2019

## SURGICAL PATHOLOGY REPORT

### GALL BLADDER.

#### DIAGNOSIS

**CHOLECYTITIS AND CHOLELITHIASIS**



#### **SPECIMEN**

Gall Bladder.

#### **GROSS**

Received 4.1x3 cm long gall bladder. Cut section shows tiny stones.

#### **Microscopy**

- Section examined shows ulcerative mucosa and Rokitansky-Aschoff sinuses (irregularly shaped tubular structures lined by cuboidal lining epithelium with round to oval nucleus) with fibrocollagenous tissue, calcifications and inflammatory cells (lymphocytes).

**Note :** All biopsy specimen will be stored for 15 (fifteen) days, block and slides for 5 (five) years only from the time of receipt at the laboratory. No request ,for any of the above will be entertained after the due date.

#### **Reference**

- Rosai and Ackerman's Surgical Pathology.
- Modern Surgical Pathology.

**Gulshan Yadav, MD**  
Consultant Pathologist