

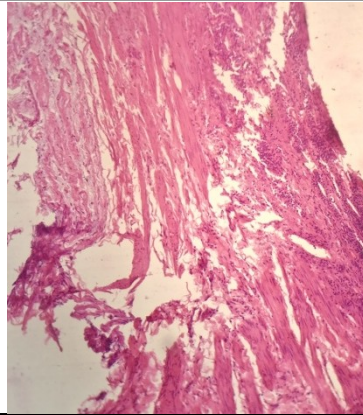
Patient Name	Mr. SUDHEER SINGH	Client Name	Accurate Path (C), Agra	Specimen Received	26-Mar-2019
Age/Sex	35/M	Client Code	MolQ1671CM	Specimen Type	Tissue
Patient ID	011903260021	Ref. Doctor		Collection Date	26-Mar-2019
Specimen ID	MOLQ/B-504/19			Report Date	29-Mar-2019

SURGICAL PATHOLOGY REPORT

GALL BLADDER.

DIAGNOSIS

CHOLECYTITIS AND CHOLELITHIASIS



SPECIMEN

Gall Bladder.

GROSS

Received autolyzed 6.2x2.8 cm long gall bladder. Cut section shows multiple stones.

Microscopy

- Section examined shows ulcerative mucosa and Rokitansky-Aschoff sinuses (irregularly shaped tubular structures lined by cuboidal lining epithelium with round to oval nucleus) with fibrocollagenous tissue, calcifications and inflammatory cells (lymphocytes).

Note : All biopsy specimen will be stored for 15 (fifteen) days, block and slides for 5 (five) years only from the time of receipt at the laboratory. No request ,for any of the above will be entertained after the due date.

Reference

- Rosai and Ackerman's Surgical Pathology.
- Modern Surgical Pathology.

**Gulshan Yadav, MD
Consultant Pathologist**