

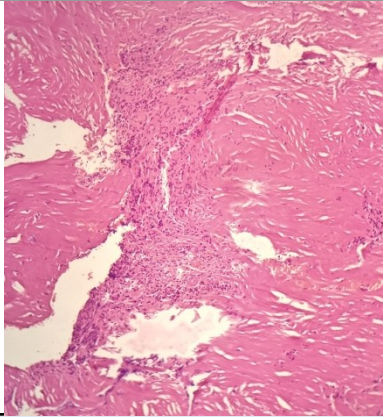
Patient Name	Ms. DIPALI	Client Name	Shri Balaji Multispeciality	Specimen Received	25-Mar-2019
Age/Sex	51/F		Gurgaon	Specimen Type	Tissue
Patient ID	011903250198	Client Code	MolQ1269CM	Collection Date	25-Mar-2019
Specimen ID	MOLQ/B-502/19	Ref. Doctor		Report Date	29-Mar-2019

SURGICAL PATHOLOGY REPORT

GALL BLADDER.

DIAGNOSIS

HYALINIZING CHOLECYSTITIS WITH CHOLELITHAISIS



SPECIMEN

Gall Bladder.

GROSS

Received 4x2.8 cm greyish white tissue piece.

Microscopy

- Section examined shows ulcerative mucosa and rokitansky aschoff sinus (irregularly shaped tubular structures lined by cuboidal lining epithelium with round to oval nucleus) with fibro collagenous tissue, calcifications and inflammatory cells (lymphocytes).

Note : All biopsy specimen will be stored for 15 (fifteen) days, block and slides for 5 (five) years only from the time of receipt at the laboratory. No request ,for any of the above will be entertained after the due date.

Reference

- Rosai and Ackerman's Surgical Pathology.
- Modern Surgical Pathology.

**Gulshan Yadav, MD
Consultant Pathologist**